



## BRAINWARE UNIVERSITY

Term End Examination 2023-2024

Programme – B.Sc.(MRIT)-2022

Course Name – Contrast & Special Radiography Procedures

Course Code - BMRITS304

( Semester III )

Full Marks : 60

Time : 2:30 Hours

[The figure in the margin indicates full marks. Candidates are required to give their answers in their own words as far as practicable.]

### Group-A

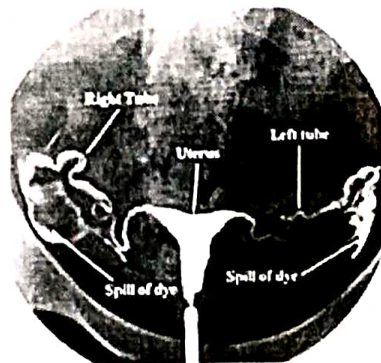
(Multiple Choice Type Question)

1 x 15=15

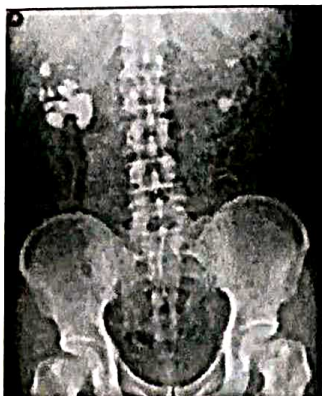1. Choose the correct alternative from the following :

- (i) Tell the full form of LMP in female patients
- |                          |                      |
|--------------------------|----------------------|
| a) Last Menstrual Period | b) Last Month Period |
| c) Long Menstrual Period | d) Long month Period |
- (ii) Enumerate the full form of IVU
- |                              |                               |
|------------------------------|-------------------------------|
| a) Intravenous urethrography | b) Intravenous Ureterography  |
| c) Intravenous Urography     | d) Intravenous Urethralgraphy |
- (iii) Predict the duration of spot film MCU
- |                           |                               |
|---------------------------|-------------------------------|
| a) After the micturation  | b) Before the micturition     |
| c) During the micturation | d) Before filling the bladder |
- (iv) Estimate the patient position during HSG procedure.
- |           |              |
|-----------|--------------|
| a) Supine | b) lithotomy |
| c) Prone  | d) Decbitus  |
- (v) Identify which of the following is not a common type of contrast media used in radiology.
- |                                     |                                 |
|-------------------------------------|---------------------------------|
| a) Barium sulfate                   | b) Iodine-based contrast agents |
| c) Gadolinium-based contrast agents | d) Nitrous oxide                |
- (vi) Select the correct statement about contrast media used in radiologys
- |  |   |
|--|---|
| a) Contrast media is used to make the image darker | b) Contrast media is used to make the image lighter                   |
| c) Contrast media is not used in radiology         | d) Contrast media is used to highlight certain structures in the body |
- (vii) Select the emergency drug used to treat cardiac arrest.
- |              |                  |
|--------------|------------------|
| a) Adenosine | b) Nitroglycerin |
| c) Atropine  | d) Epinephrine   |
- (viii) Choose the emergency drug used to treat hypoglycemia.
- |                 |            |
|-----------------|------------|
| a) Pioglitazone | b) Insulin |
|-----------------|------------|

- c) Glucagon  
d) Metformin
- (ix) Identify the primary purpose of using lead shielding during a radiological procedure:  
a) To make the equipment more durable  
b) To reduce radiation exposure to the patient  
c) To increase the weight of the imaging equipment  
d) To improve image quality
- (x) Omit correct statement "proper infection control measures can result in"  
a) Reduced waiting times  
b) Enhanced patient comfort  
c) Increased risk of healthcare-associated infections  
d) Improved image resolution
- (xi) Choose which type of contrast media is typically administered orally or rectally for gastrointestinal imaging?  
a) Iodinated contrast  
b) Gadolinium-based contrast  
c) Barium sulfate  
d) Air contrast
- (xii) Omit the route of contrast administration  
a) Oral  
b) Intramuscular  
c) Intravenous  
d) Enema
- (xiii) Identify the name of special radiographic procedure from the below mentioned image.



- a) HSG  
b) Cystography  
c) IVP  
d) MCU
- (xiv) Identify the primary purpose of a barium meal follow-through procedure.  
a) To diagnose fractures in bones  
b) To assess kidney function  
c) To evaluate the gastrointestinal tract  
d) To examine the brain's blood vessels
- (xv) Predict the abnormal finding from the below mentioned image.



- a) Horseshoe Kidney  
b) Renal Mass  
c) Staghorn Calculi  
d) None of these

**Group-B**  
(Short Answer Type Questions)

3 x 5=15

2. Write a note on 10 day rule 28 days rule (3)
3. Explain why Iodine is used as a contrast media. (3)
4. Describe the indications of sialography. (3)
5. Explain the anatomy of small and large intestine. (3)
6. Summarize the technique of Bronchography. (3)

**OR**

Explain the indications of Endoscopic retrograde cholangio-pancreatography (ERCP) (3)

**Group-C**

(Long Answer Type Questions)

5 x 6=30

7. Summarize mammographic image evaluation (5)
8. Explain the responsibilities of radiographer during Contrast administration (5)
9. Write about the working of barium contrast with its properties that make it suitable for imaging the gastrointestinal tract. (5)
10. Differentiate between High osmolarity and Low osmolarity contrast media (5)
11. Describe in detail about BIRADS (5)
12. Explain in detail about PTC. (5)

**OR**

Explain the radiological anatomy of tracheobronchial tree. (5)

\*\*\*\*\*